

# Acellular Dermal Matrix–Assisted Direct-to-Implant Breast Reconstruction and Capsular Contracture: A 13-Year Experience

C. Andrew Salzberg, M.D.  
 Andrew Y. Ashikari, M.D.  
 Colleen Berry, A.R.N.P.,  
 F.N.P.-B.C.  
 Lisa M. Hunsicker, M.D.

*New York, N.Y.;  
 and Littleton, Colo.*



**Background:** Use of acellular dermal matrix for implant-based breast reconstruction appears to be associated with a lower incidence of capsular contracture compared with standard reconstruction. The majority of acellular dermal matrix studies were, however, of short duration; thus, long-term incidence of capsular contracture with acellular dermal matrix use is unknown.

**Methods:** Patients undergoing acellular dermal matrix–assisted breast reconstruction from December of 2001 to May of 2014 at two institutions were evaluated. Cumulative incidence of capsular contracture was determined by the performing surgeon. A retrospective chart review was performed on prospectively gathered data on patient-, breast-, surgery-, and implant-related characteristics that were analyzed as potential risk factors for the development of capsular contracture.

**Results:** A total of 1584 breast reconstructions in 863 patients were performed. Mean follow-up of patients was 4.7 years; 45 percent of patients had greater than or equal to 5 years of follow-up. The cumulative incidence of capsular contracture was 0.8 percent. Smaller implant size (<400 ml) and postoperative radiotherapy were significantly associated with an increased risk of capsular contracture, but the incidence of capsular contracture was 1.9 percent in irradiated breasts. All capsular contractures developed within the first 2 years, with no new events with longer follow-up.

**Conclusions:** In this long-term study, the cumulative incidence of capsular contracture with acellular dermal matrix–assisted reconstruction remains low, even in irradiated breasts. Capsular contracture appears to be an early event, and longer follow-up does not appear to increase the incidence, suggesting that acellular dermal matrix may truly mitigate the development of capsular contracture as opposed to delaying its occurrence. (*Plast. Reconstr. Surg.* 138: 329, 2016.)

**CLINICAL QUESTION/LEVEL OF EVIDENCE:** Therapeutic, IV.

Clinically significant capsular contracture is one of the most frequent long-term complications associated with implant-based breast reconstruction. The reported incidence in core clinical studies of implant manufacturers ranges

from 3 to 25 percent in patients followed over a 2- to 10-year period (Fig. 1).<sup>1–12</sup> Two observations can be made from these data: first, capsular contracture appears to be a progressive phenomenon, with incidence increasing with longer follow-up; and second, improvements in implant design appear to diminish the incidence. Newer implants, including form-stable implants, appear to have a lower incidence (6-year rate, 10 to 11 percent) compared with classic round implants (6-year rate, 8 to 16 percent).

*From the Icahn School of Medicine, Mount Sinai Health Systems; the Ashikari Breast Center; and Revalla Plastic Surgery & Medical Aesthetics.*

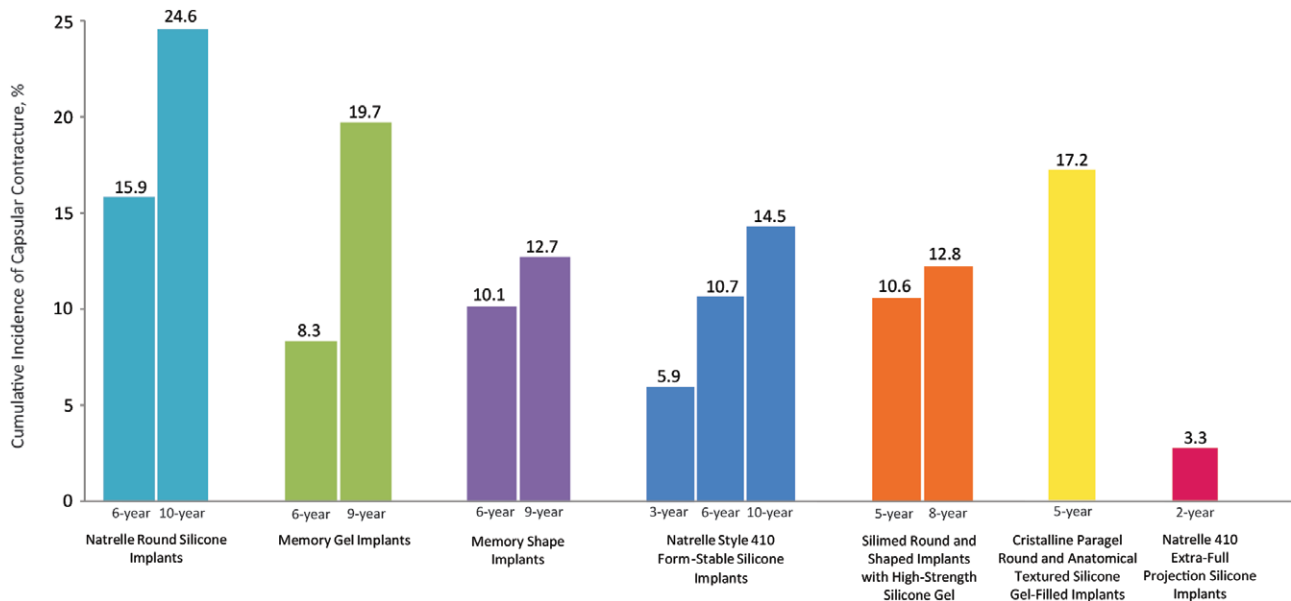
*Received for publication December 16, 2015; accepted March 14, 2016.*

*Presented in part at Plastic Surgery The Meeting 2014, Annual Meeting of the American Society of Plastic Surgeons, in Chicago, Illinois, October 10 through 14, 2014; and the 53rd Annual Scientific Meeting of the Northwest Society of Plastic Surgeons, in Kailua-Kona, Hawaii, February 14 through 18, 2015.*

*Copyright © 2016 by the American Society of Plastic Surgeons*

DOI: 10.1097/PRS.0000000000002331

**Disclosure:** Dr. Hunsicker and Dr. Ashikari are consultants to LifeCell Corporation. Ms. Berry and Dr. Salzberg have no relevant disclosures. No funds were received or utilized for the research presented in this article.



**Fig. 1.** Cumulative incidence of capsular contracture in primary reconstruction patients reported in core studies of implant manufacturers: (left) Natrelle Round Silicone Implants<sup>3,9</sup>; (second from left) MemoryGel (Round) Implants<sup>2,7</sup>; (third from left) MemoryShape Implants (formerly Contour Profile Gel)<sup>4,7</sup>; (center) Natrelle Style 410 Form-Stable Silicone Implants<sup>1,5,10</sup>; (third from right) Silimed Round and Shaped Implants with High-Strength Silicone Gel<sup>6,12</sup>; (second from right) Crystalline Paragel Round and Anatomical Textured Silicone Gel-Filled Mammary Implant<sup>8</sup>; (right) Natrelle 410 Extra-Full Projection Silicone Implants.<sup>11</sup>

The introduction of acellular matrices in breast reconstruction over the past decade has coincided with a reduction in the incidence of capsular contracture. A pooled analysis of 16 studies placed the incidence at 0.6 percent,<sup>13</sup> 3- to 40-fold lower than the incidence reported in the core studies. Pathophysiologic studies have further provided mechanistic explanations for the observed low incidence of capsular contracture.<sup>14,15</sup> Considered together, these data suggest that acellular matrices may have the potential to mitigate the risk of capsular contracture. However, several questions remain.

First, is acellular matrix actually diminishing the risk of capsular contracture or is it simply delaying the risk? That is, will longer follow-up increase the risk? The duration of follow-up in the acellular matrix studies ranged from 0.5 to 1.5 years, and data from the Core Clinical Studies indicate that the incidence increases over time. Second, does the use of acellular matrix protect against the development of radiation-induced capsular contracture? Third, are there patient-, surgery-, or implant-related characteristics that influence the incidence of capsular contracture in acellular dermal matrix-assisted reconstructions? This study attempts to address these questions using data from a large cohort of patients who underwent acellular dermal matrix-assisted, direct-to-implant reconstruction over a period of 13 years at two institutions.

## PATIENTS AND METHODS

All patients who underwent acellular dermal matrix-assisted, direct-to-implant breast reconstruction following mastectomy, from December of 2001 to May of 2014, in the authors' practices were included in this institutional review board-approved (Porter Adventist Hospital, Denver, Colo.), retrospective study. Patients who underwent revision reconstruction, who had expandable implants, or who had a flap procedure in conjunction with implant placement were excluded. Patients were followed initially every 3 months for the first year after reconstruction and then annually or as needed. Patients who had left the practice were contacted to obtain data on capsular contracture events that may have occurred during the study period. Capsular contracture was evaluated by the performing reconstructive surgeon (L.M.H. or C.A.S.). All incidences of clinically significant capsular contracture, defined by a Spear-Baker grade III or IV,<sup>16</sup> that occurred during the study period were recorded together with the date of onset of contracture or the date of corrective surgery and the method of resolution.

A retrospective chart review was performed to extract data on patient-, breast-, surgery-, and implant-related characteristics that were analyzed as potential risk factors for the development of capsular contracture. Data on the following

characteristics were collected: patient age, body mass index, and smoking status; reason for surgery (prophylactic versus oncologic); radiotherapy (preoperative and/or postoperative); mastectomy type (nipple-sparing mastectomy or non-nipple-sparing mastectomy); incision site (inframammary fold, lateral mammary fold, traditional, or periareolar); implant size; and implant surface characteristic (smooth or textured). In addition, the influence of postoperative complications, particularly seroma/hematoma and overt infection before the development of capsular contracture, were also evaluated as potential risk factors. Postoperative complications occurring within the first 12 months after direct-to-implant reconstruction in this cohort of patients were reported in a previous publication.<sup>17</sup>

To assess the association between the potential risk factors and development of capsular contracture, univariate analyses were initially performed (using SAS version 9.3; SAS Institute, Inc., Cary, N.C.) with chi-square test for categorical variables and logistic regression for continuous variables. For continuous variables, a threshold was also identified and used as the cutoff for conversion of the continuous variable to a categorical variable. Variables that were statistically significant ( $p < 0.05$ ) at the univariate level were reassessed in a multiple logistic regression model. To assess whether length of follow-up increases the incidence of capsular contracture, a Kaplan-Meier analysis was performed using individual patient-level data.

## RESULTS

### Patient and Implant Characteristics

A total of 1584 direct-to-implant reconstructions were performed in 863 patients during the study period. Demographic and clinical characteristics of the patient population are as listed in Table 1. Briefly, patients had a mean age of 47.0 years and a mean body mass index of 24.4 kg/m<sup>2</sup>. Approximately 14 percent were smokers or had a history of smoking, whereas other comorbidities such as hypertension, diabetes, and obesity were each present in less than 10 percent of patients. A quarter of the patients had chemotherapy and one-tenth were treated with radiotherapy. Sixty-five percent of the mastectomies were prophylactic mastectomies. The majority of the mastectomies were performed as nipple-sparing mastectomies (66 percent), typically through inframammary (49 percent) or traditional transverse (35 percent) incisions. AlloDerm (LifeCell Corp., Branchburg, N.J.) was the predominant acellular

**Table 1. Patient Demographics, Adjuvant Therapy, and Mastectomy and Implant Characteristics**

Characteristic	Value (%)
No. of patients	863
No. of breasts	1584
Age, yr	
Mean $\pm$ SD	47.0 $\pm$ 10.0
Range	21–77
Body mass index, kg/m <sup>2</sup>	
Mean $\pm$ SD	24.4 $\pm$ 4.8
Range	16–54
Comorbidities, no. of patients	
Diabetes	14 (1.6)
Smoking (current or history)	118 (13.7)
Hypertension	83 (9.6)
Obesity*	85 (9.8)
Chemotherapy, no. of patients	227 (26.3)
Radiotherapy	
No. of patients	100 (11.6)
No. of breasts	104 (6.6)
Before mastectomy	44 (42.3)
After mastectomy	52 (50.0)
History	8 (7.7)
Mastectomy	
Bilateral, no. of patients	721 (83.5)
Unilateral, no. of patients	142 (16.5)
Prophylactic, no. of breasts	1024 (64.6)
Oncologic, no. of breasts	560 (35.4)
Weight, mean $\pm$ SD, g	
Mean $\pm$ SD	419.0 $\pm$ 313.4
Range	35–2846
Nipple-sparing, no. of breasts	
Yes	1043 (65.9)
No	541 (34.2)
Incision site, no. of breasts	
Periareolar	6 (0.4)
Inframammary fold	774 (48.9)
Lateral mammary fold	196 (12.4)
Traditional	552 (34.8)
Wise pattern	33 (2.1)
Implant size, ml	
Mean $\pm$ SD	484.8 $\pm$ 123.8
Range	100–800
Implant surface, no. of breasts	
Smooth	1529 (96.5)
Textured	55 (3.5)
Acellular dermal matrix used, no. of breasts	
AlloDerm	1473 (93.0)
Strattice	109 (6.9)
FlexHD	2 (0.1)

\*Body mass index  $\geq$  30 kg/m<sup>2</sup>.

dermal matrix used in the reconstructions, in 93 percent of the reconstructions, whereas Strattice (LifeCell) was used in 6.9 percent and FlexHD (Ethicon, Inc., Somerville, N.J.) was used in 0.1 percent of the reconstructions. Almost all of the implants placed were smooth implants; textured implants constituted 4 percent of the implants. Implants ranged in size from 100 to 800 ml, with a mean of 485 ml.

### Incidence of Capsular Contracture

Patients were followed for a mean of 4.7  $\pm$  2.7 years (range, 0.6 to 13.2 years) after reconstructive

**Table 2. Follow-Up Duration\***

Years of Follow-Up	No. (%)
≥1	806 (93.4)
≥2	681 (78.9)
≥3	572 (66.3)
≥4	480 (55.6)
≥5	386 (44.7)
≥6	273 (31.6)
≥7	178 (20.6)
≥8	92 (10.7)
≥9	54 (6.3)
≥10	23 (2.7)
≥11	15 (1.7)

\*n = 863 patients.

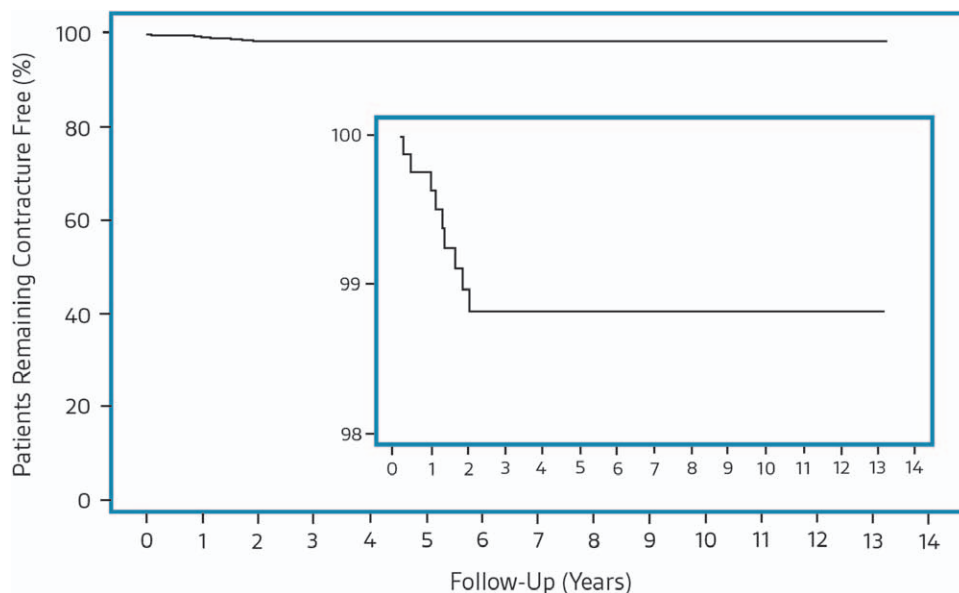
surgery; 93 percent were followed for at least 1 year, 79 percent for at least 2 years, 66 percent for at least 3 years, 56 percent for at least 4 years, and 45 percent for at least 5 years (Table 2). Clinically significant capsular contracture was diagnosed in nine patients (12 breasts), for a capsular contracture rate of 1.0 percent at the patient level and 0.8 percent at the breast level. All capsular contracture events occurred within the first 2 years after reconstructive surgery (Fig. 2). Four patients (seven breasts) underwent corrective surgery that involved capsulotomy with implant removal and replacement. No intervention has been planned in the remaining patients.

### Risk Factors for Development of Capsular Contracture

Eleven factors were analyzed as potential risk factors for the development of capsular contracture, including patient age; body mass index; smoking; oncologic breast; nipple-sparing

mastectomy; incision site; implant size; implant surface characteristic; radiotherapy; and postoperative seroma, hematoma, and/or infection before capsular contracture. All breasts that had contracture had smooth implants, and none had preoperative radiotherapy or seroma/hematoma/infection before the development of capsular contracture. In fact, none of the breasts had any overt complications before the development of capsular contracture, although there were 48 cases of infection requiring intravenous antibiotic treatment (3.0 percent), 17 cases of seroma (1.1 percent), and 15 cases of hematoma (0.9 percent) in the entire cohort.<sup>17</sup>

On univariate analysis, implant size was the only statistically significant factor associated with the development of capsular contracture (Table 3). Patients with smaller implants (<400 ml) had a 5.6-fold increased odds for developing contracture. When implant size was further stratified into 100-ml increases starting from 300 ml, there appeared to be a possible association, suggesting that as implant size increased, the incidence of contracture decreased. Body mass index and postoperative radiotherapy also showed a possible association with the development of capsular contracture ( $p < 0.1$ ). All incidences of capsular contracture occurred in patients with a body mass index less than 30 kg/m<sup>2</sup>, and patients who had postoperative radiotherapy had a 6.1-fold increased odds for developing contracture. Overall, irradiated patients (preoperative and postoperative radiotherapy combined) had a 2.9-fold increased odds for developing contracture



**Fig. 2.** Kaplan-Meier plot of cumulative incidence of capsular contracture by patient.

compared with those who were not irradiated (1.9 percent versus 0.7 percent), but the increase in odds was not statistically significant ( $p = 0.1837$ ).

Implant size (<400 versus  $\geq 400$  ml), body mass index (as a continuous variable), and postoperative radiotherapy (yes versus no) were further evaluated in a multiple logistic regression analysis. Implant

**Table 3. Univariate Analyses of Potential Risk Factors for the Development of Capsular Contracture**

Risk Factor	CC Events %	OR (95% CI)	<i>p</i>
Patient-related			
Age, yr			
<30	0	NE	0.5832
30–39	1.56		
40–49	0.94		
50–59	0.54		
60–69	0.84		
$\geq 70$	0		
BMI, kg/m <sup>2</sup>			
<25	0.55	NE	0.0534†
25–29	1.99		
30–34	0		
$\geq 35$	0		
Smoking			
Yes	1.39	1.94 (0.52–7.24)	0.4010
No	0.72		
Chemotherapy			
Yes	1.45	2.53 (0.81–7.88)	0.1124
No	0.58		
Breast-related			
Oncologic breast			
Yes	0.89	1.31 (0.41–4.14)	0.7633
No	0.68		
Radiotherapy			
Yes	1.92	2.88 (0.62–13.33)	0.1837
No	0.68		
Preoperative			
Yes	0	NE	1.000
No	0.78		
Postoperative			
Yes	3.85	6.09 (1.30–28.51)	0.0565†
No	0.65		
Surgery-related			
Nipple-sparing			
Yes	0.69	0.74 (0.24–2.36)	0.7620
No	0.92		
Incision type			
Inframammary fold	0.78	NE	0.9619
Lateral mammary fold	0.51		
Periareolar	0		
Traditional	0.91		
Wise pattern reduction	0		
Implant-related			
Implant surface			
Smooth	0.78	NE	1.00
Textured	0		
Implant size, ml			
<400	2.13	5.56 (1.72–16.67)	0.0047*
$\geq 400$	0.40		

(Continued)

**Table 3. Continued**

Risk Factor	CC Events %	OR (95% CI)	<i>p</i>
Implant size strata, ml			
<300	3.13	4.10 (0.36–46.05)	0.0211*
300–399	2.10	2.73 (0.31–23.58)	
400–499	0.34	0.43 (0.04–4.77)	
500–599	0.33	0.42 (0.03–6.80)	
600–699	0.43	0.55 (0.03–8.90)	
700–800	0.78	—	
Postoperative complication-related			
Seroma/hematoma before CC			
Yes	0	NE	1.00
No	0.77		
Overt infection before CC			
Yes	0	NE	1.00
No	0.78		

CC, capsular contracture; NE, not estimable; BMI, body mass index.

\*Statistically significant.

†Possible association with the development of capsular contracture ( $p < 0.1$ ).

size and postoperative radiotherapy emerged as strong predictors for the development of capsular contracture, whereas body mass index was no longer predictive (Table 4). Patients with smaller implants (<400 ml) had a 10.3-fold increased odds for developing capsular contracture, whereas those who were irradiated postoperatively had a 7.1-fold increased odds for developing contracture.

## DISCUSSION

Clinically significant capsular contracture, defined as grade III/IV on the Spear-Baker classification scheme, is characterized by implant firmness/tightness, deformation, dislocation, and pain.<sup>16</sup> Although not a life-threatening complication, capsular contracture causes significant discomfort and psychological distress, and adversely impacts the quality of life of afflicted individuals. Corrective surgery is the only treatment for capsular contracture; however, it is not foolproof, and the recurrence rate is high.<sup>18</sup> There are also no known reliable preventative measures. The prevention and management of capsular contracture has thus been a challenge in breast reconstructive surgery since the introduction of breast implants more than half a century ago.

Numerous short-term studies have reported a low incidence of capsular contracture when reconstructions are performed with the use of acellular dermal matrix.<sup>13</sup> This observation has been confirmed in a comparative study that found a significantly lower incidence of capsular contracture in

**Table 4. Multivariate Risk Factor Analysis for the Development of Capsular Contracture**

Risk Factor	OR (95% CI)	<i>p</i>
Implant size (<400 vs. ≥400), ml	10.30 (2.65–40.09)	0.0008
BMI (1 point increase), kg/m <sup>2</sup>	1.098 (0.985–1.22)	0.0910
Postoperative radiotherapy (yes vs. no)	7.14 (1.42–35.71)	0.0168

BMI, body mass index.

acellular dermal matrix–assisted reconstructions versus standard reconstructions.<sup>19</sup> Because most of the acellular dermal matrix studies were small cohort studies with short follow-up duration, larger, longer term studies are needed to confirm the lower incidence in the presence of acellular dermal matrix. We have previously reported our 8-year data (mean follow-up, 2.4 years) where we demonstrated a capsular contracture rate of 0.4 percent in acellular dermal matrix–assisted, direct-to-implant reconstructions.<sup>20</sup> Extending on those data, together with data from another practice (L.M.H. and C.B.), we report here the combined capsular contracture outcomes in 1584 reconstructions over a 13-year period and explore potential risk factors for the development of capsular contracture in acellular dermal matrix–assisted reconstructions.

At a mean follow-up of 4.7 years, our capsular contracture rate has remained low at 0.8 percent. Within the same timeframe, the incidence reported in the core studies ranged from 8 to 17 percent, 10- to 20-fold higher (Fig. 1).<sup>1–12</sup> In addition, all capsular contracture events in our cohort developed within the first 2 years after reconstructive surgery. In the core studies, approximately 50 to 75 percent of capsular contractures developed within the first 5 to 6 years (Fig. 1). Three observations can be made from our present analyses: (1) capsular contracture appears to be an early event in acellular dermal matrix–assisted reconstructions; (2) capsular contracture does not appear to progress over time in acellular dermal matrix–assisted reconstructions, at least not in the same timeframe as in standard reconstructions; and (3) acellular dermal matrix does not appear to delay capsular contracture, again in the same timeframe as in standard reconstructions, and that it may actually mitigate capsular contracture from occurring. This last observation corroborates with pathophysiologic findings that suggest that acellular dermal matrix may serve as a barrier to the host's foreign body immune response.<sup>14,15</sup>

In addition to the length of follow-up, a number of other factors such as age, smooth implant surface, periareolar incision, hematoma or seroma before the development of capsular contracture, and irradiation have been associated with an increased incidence of capsular contracture in standard

reconstructions.<sup>21,22</sup> We explored the influence of these factors and body mass index, smoking status, prophylactic versus oncologic breast, nipple-sparing mastectomy versus non–nipple-sparing mastectomy, postoperative infectious complications, and implant size on the development of capsular contracture in our cohort of acellular dermal matrix–assisted reconstructions. Of the variables, implant size and postoperative radiotherapy were significantly associated with the development of capsular contracture. In particular, implant sizes smaller than 400 ml were associated with an increased incidence of contracture. There also appeared to be a possible association suggesting that as implant size increased, the incidence of contracture decreased. This same relationship between implant size and capsular contracture was reported by Stevens et al. in patients who underwent augmentation mammoplasty (without the use of acellular dermal matrix).<sup>22</sup> It is, however, counterintuitive that larger implants should have a lower risk of contracture, because larger breasts are generally associated with a higher risk of postoperative complications.<sup>23,24</sup> One likely explanation for this inverse relationship between implant size and contracture may be related to the dissipation of tension arising from contracture within the implant/breast. Larger breasts may be better able to dissipate the tension, given their larger volume compared with smaller breasts.

It is well known that preoperative or postoperative irradiation substantially increases the incidence of capsular contracture in standard reconstructions.<sup>25–28</sup> Given the lower incidence of contracture with acellular dermal matrix use, the expectation is that acellular dermal matrix may protect against the deleterious effects of radiotherapy. The majority of acellular dermal matrix studies have predominantly included nonirradiated cohorts, although some studies did include irradiated patients who did not appear to have an increased risk of contracture.<sup>29–35</sup> Two studies that specifically evaluated the incidence of capsular contracture in irradiated patients have, however, reported higher incidences of contracture in irradiated versus nonirradiated breasts.<sup>36,37</sup> Spear et al. reported the following capsular contracture rates: 41.2 percent in breasts irradiated before mastectomy (*n* = 17), 60.7 percent in breasts irradiated with the

expander ( $n = 56$ ), and 1.4 percent in nonirradiated breasts ( $n = 355$ ). Moyer et al. reported a capsular contracture rate of 33.3 percent in irradiated breasts ( $n = 9$  patients) and 0 percent in nonirradiated breasts ( $n = 18$  patients). Our present study included a total of 104 irradiated breasts, the largest irradiated cohort reported thus far. In this large sample, although there was an increased incidence of capsular contracture in irradiated breasts, it was not statistically significant. In addition, the capsular contracture rate in irradiated breasts was a low 1.9 percent. With respect to the timing of irradiation, the two cases of contracture in irradiated breasts occurred after postoperative irradiation. Our overall low incidence of capsular contracture in irradiated breasts calls for further controlled studies with or without acellular matrix and with or without irradiation to fully explore the relationship between acellular matrix use and capsular contracture in the setting of radiotherapy.

As with the prevention and treatment of capsular contracture, the cause of capsular contracture has remained elusive. However, current evidence suggests that subclinical infection with bacterial biofilms in the periprosthetic space could be the inciting event that drives the uncontrolled inflammatory response that leads to capsular contracture.<sup>38,39</sup> Not surprisingly, seroma/hematoma that could harbor infection has been shown to be an independent risk factor for the development of contracture.<sup>22</sup> Interestingly, in our cohort, none of the patients who had seroma/hematoma or overt infection that required intravenous antibiotic treatment had capsular contracture. Moreover, none of the breasts that developed contracture had any overt postoperative complications; however, we cannot exclude the possibility of subclinical infection or subclinical seromas.

Retrospective analyses, the absence of a non-acellular dermal matrix control group, and the subjectivity of the Spear-Baker grading scale used for the evaluation of capsular contracture are limitations of this study. Furthermore, the low incidence of capsular contracture (0.8 percent at the breast level and 1.0 percent at the patient level) makes it difficult to evaluate risk factors for the development of contracture.

## CONCLUSIONS

In this study spanning 13 years, the cumulative incidence of capsular contracture with acellular dermal matrix–assisted, direct-to-implant reconstruction remains low, even in irradiated breasts. Capsular contracture appears to be an early event, occurring within the first 2 years after

reconstruction. Longer follow-up does not appear to increase the incidence, suggesting that acellular matrix may truly diminish the development of capsular contracture. Patient-, surgery-, breast, and implant-related characteristics, with the exception of implant size and postoperative irradiation, do not appear to influence the development of capsular contracture. Larger, controlled studies are needed to further explore our findings and observations.

## CODING PERSPECTIVE



Coding perspective provided by Dr. Raymund Janevicius is intended to provide coding guidance.

- 19340 Immediate insertion of breast prosthesis following mastopexy, mastectomy or in reconstruction
- +15777 Implantation of biologic implant (e.g., acellular dermal matrix) for soft tissue reinforcement (i.e., breast, trunk) (List separately in addition to code for primary procedure)

- The direct-to-implant breast reconstruction is performed at the time of mastectomy. This is an immediate reconstruction, so code 19340 is reported.
- The placement of acellular dermal matrix (a biologic implant) is reported with code 15777. This code is an add-on code, i.e., it is always reported with another code, so the multiple procedure modifier, 51, is **not** used.
- Bilateral procedures are reported using modifier 50:

19340 Immediate insertion of breast prosthesis, right

19340-50 Immediate insertion of breast prosthesis, left

15777 Implantation of biologic implant (e.g., acellular dermal matrix), right

15777-50 Implantation of biologic implant (e.g., acellular dermal matrix), left

- Some payers, including Medicare, require single-line reporting:

19340-50 Immediate insertion of breast prosthesis, bilateral

15777-50 Implantation of biologic implant (e.g., acellular dermal matrix), bilateral

C. Andrew Salzberg, M.D.  
Icahn School of Medicine  
Mount Sinai Health Systems  
New York, N.Y.  
asalzbergmd@yahoo.com

### ACKNOWLEDGMENTS

An educational grant from LifeCell Corp. was used for data analyses and article preparation. We would like to thank Kalanethee Paul-Pletzer, Ph.D. (LifeCell Corp.), for providing medical writing support and Leah Passmore Griffin, M.S. (Acelity, San Antonio, Texas), for providing statistical analyses support for this article.

### REFERENCES

- Bengtson BP, Van Natta BW, Murphy DK, Slicton A, Maxwell GP; Style 410 U.S. Core Clinical Study Group. Style 410 highly cohesive silicone breast implant core study results at 3 years. *Plast Reconstr Surg.* 2007;120(Suppl 1):40S–48S.
- Cunningham B. The Mentor Study on Contour Profile Gel Silicone MemoryGel Breast Implants. *Plast Reconstr Surg.* 2007;120(Suppl 1):33S–39S.
- Spear SL, Murphy DK, Slicton A, Walker PS; Inamed Silicone Breast Implant U.S. Study Group. Inamed silicone breast implant core study results at 6 years. *Plast Reconstr Surg.* 2007;120(Suppl 1):8S–16S; discussion 17S.
- Hammond DC, Migliori MM, Caplin DA, Garcia ME, Phillips CA. Mentor Contour Profile Gel implants: Clinical outcomes at 6 years. *Plast Reconstr Surg.* 2012;129:1381–1391.
- Maxwell GP, Van Natta BW, Murphy DK, Slicton A, Bengtson BP. Natrele style 410 form-stable silicone breast implants: Core study results at 6 years. *Aesthet Surg J.* 2012;32:709–717.
- Stevens WG, Harrington J, Alizadeh K, et al. Five-year follow-up data from the U.S. clinical trial for Sientra's U.S. Food and Drug Administration-approved Silimed brand round and shaped implants with high-strength silicone gel. *Plast Reconstr Surg.* 2012;130:973–981.
- Caplin DA. Indications for the use of MemoryShape breast implants in aesthetic and reconstructive breast surgery: Long-term clinical outcomes of shaped versus round silicone breast implants. *Plast Reconstr Surg.* 2014;134(Suppl):27S–37S.
- Duteille F, Rouif M, Laurent S, Cannon M. Five-year safety data for Eurosilicone's round and anatomical silicone gel breast implants. *Plast Reconstr Surg Glob Open* 2014;2:e138.
- Spear SL, Murphy DK; Allergan Silicone Breast Implant U.S. Core Clinical Study Group. Natrele round silicone breast implants: Core Study results at 10 years. *Plast Reconstr Surg.* 2014;133:1354–1361.
- Maxwell GP, Van Natta BW, Bengtson BP, Murphy DK. Ten-year results from the Natrele 410 anatomical form-stable silicone breast implant core study. *Aesthet Surg J.* 2015;35:145–155.
- Cordeiro PG, McGuire P, Murphy DK. Natrele 410 extra-full projection silicone breast implants: 2-year results from two prospective studies. *Plast Reconstr Surg.* 2015;136:638–646.
- Stevens WG, Harrington J, Alizadeh K, Broadway D, Zeidler K, Godinez TB. Eight-year follow-up data from the U.S. clinical trial for Sientra's FDA-approved round and shaped implants with high-strength cohesive silicone gel. *Aesthet Surg J.* 2015;35(Suppl 1):S3–10.
- Ho G, Nguyen TJ, Shahabi A, Hwang BH, Chan LS, Wong AK. A systematic review and meta-analysis of complications associated with acellular dermal matrix-assisted breast reconstruction. *Ann Plast Surg.* 2012;68:346–356.
- Basu CB, Leong M, Hicks MJ. Acellular cadaveric dermis decreases the inflammatory response in capsule formation in reconstructive breast surgery. *Plast Reconstr Surg.* 2010;126:1842–1847.
- Leong M, Basu CB, Hicks MJ. Further evidence that human acellular dermal matrix decreases inflammatory markers of capsule formation in implant-based breast reconstruction. *Aesthet Surg J.* 2015;35:40–47.
- Spear SL, Baker JL Jr. Classification of capsular contracture after prosthetic breast reconstruction. *Plast Reconstr Surg.* 1995;96:1119–1123; discussion 1124.
- Hunsicker LM, Ashikari AY, Berry C, Koch RM, Salzberg CA. Short-term complications associated with acellular dermal matrix-assisted direct-to-implant breast reconstruction. *Ann Plast Surg.* E-published ahead of print February 5, 2016.
- Hester TR Jr, Ghazi BH, Moyer HR, Nahai FR, Wilton M, Stokes L. Use of dermal matrix to prevent capsular contracture in aesthetic breast surgery. *Plast Reconstr Surg.* 2012;130(Suppl 2):126S–136S.
- Vardanian AJ, Clayton JL, Roostaeian J, et al. Comparison of implant-based immediate breast reconstruction with and without acellular dermal matrix. *Plast Reconstr Surg.* 2011;128:403e–410e.
- Salzberg CA, Ashikari AY, Koch RM, Chabner-Thompson E. An 8-year experience of direct-to-implant immediate breast reconstruction using human acellular dermal matrix (AlloDerm). *Plast Reconstr Surg.* 2011;127:514–524.
- Antony AK, McCarthy C, Disa JJ, Mehrara BJ. Bilateral implant breast reconstruction: Outcomes, predictors, and matched cohort analysis in 730 2-stage breast reconstructions over 10 years. *Ann Plast Surg.* 2014;72:625–630.
- Stevens WG, Nahabedian MY, Calobrace MB, et al. Risk factor analysis for capsular contracture: A 5-year Sientra study analysis using round, smooth, and textured implants for breast augmentation. *Plast Reconstr Surg.* 2013;132:1115–1123.
- Francis SH, Ruberg RL, Stevenson KB, et al. Independent risk factors for infection in tissue expander breast reconstruction. *Plast Reconstr Surg.* 2009;124:1790–1796.
- Lanier ST, Wang ED, Chen JJ, et al. The effect of acellular dermal matrix use on complication rates in tissue expander/implant breast reconstruction. *Ann Plast Surg.* 2010;64:674–678.
- Nava MB, Pennati AE, Lozza L, Spano A, Zambetti M, Catanuto G. Outcome of different timings of radiotherapy in implant-based breast reconstructions. *Plast Reconstr Surg.* 2011;128:353–359.
- Cordeiro PG, McCarthy CM. A single surgeon's 12-year experience with tissue expander/implant breast reconstruction: Part II. An analysis of long-term complications, aesthetic outcomes, and patient satisfaction. *Plast Reconstr Surg.* 2006;118:832–839.
- Vandeweyer E, Deraemaecker R. Radiation therapy after immediate breast reconstruction with implants. *Plast Reconstr Surg.* 2000;106:56–58; discussion 59.
- Spear SL, Onyewu C. Staged breast reconstruction with saline-filled implants in the irradiated breast: Recent trends and therapeutic implications. *Plast Reconstr Surg.* 2000;105:930–942.
- Bindingnavale V, Gaon M, Ota KS, Kulber DA, Lee DJ. Use of acellular cadaveric dermis and tissue expansion in postmastectomy breast reconstruction. *J Plast Reconstr Aesthet Surg.* 2007;60:1214–1218.
- Breuing KH, Colwell AS. Inferolateral AlloDerm hammock for implant coverage in breast reconstruction. *Ann Plast Surg.* 2007;59:250–255.



31. Spear SL, Parikh PM, Reisin E, Menon NG. Acellular dermis-assisted breast reconstruction. *Aesthetic Plast Surg*. 2008;32:418–425.
32. Breuing KH, Colwell AS. Immediate breast tissue expander-implant reconstruction with inferolateral AlloDerm hammock and postoperative radiation: A preliminary report. *Eplasty* 2009;9:e16.
33. Glasberg SB, Light D. AlloDerm and Strattice in breast reconstruction: A comparison and techniques for optimizing outcomes. *Plast Reconstr Surg*. 2012;129:1223–1233.
34. Mowlds DS, Salibian AA, Scholz T, Paydar KZ, Wirth GA. Capsular contracture in implant-based breast reconstruction: Examining the role of acellular dermal matrix fenestrations. *Plast Reconstr Surg*. 2015;136:629–635.
35. Hille-Betz U, Kniebusch N, Wojcinski S, et al. Breast reconstruction and revision surgery for implant-associated breast deformities using porcine acellular dermal matrix: A multicenter study of 156 cases. *Ann Surg Oncol*. 2015;22:1146–1152.
36. Spear SL, Seruya M, Rao SS, et al. Two-stage prosthetic breast reconstruction using AlloDerm including outcomes of different timings of radiotherapy. *Plast Reconstr Surg*. 2012;130:1–9.
37. Moyer HR, Pinell-White X, Losken A. The effect of radiation on acellular dermal matrix and capsule formation in breast reconstruction: Clinical outcomes and histologic analysis. *Plast Reconstr Surg*. 2014;133:214–221.
38. Rieger UM, Mesina J, Kalbermatten DF, et al. Bacterial biofilms and capsular contracture in patients with breast implants. *Br J Surg*. 2013;100:768–774.
39. Rieger UM, Raschke GF, Frei R, Djedovic G, Pierer G, Trampuz A. Role of bacterial biofilms in patients after reconstructive and aesthetic breast implant surgery. *J Long Term Eff Med Implants* 2014;24:131–138.

### American Society of Plastic Surgeons Mission Statement

The mission of the American Society of Plastic Surgeons® is to support its members in their efforts to provide the highest quality patient care and maintain professional and ethical standards through education, research, and advocacy of socioeconomic and other professional activities.